

2. Tas S, Simonart T. Management of drug rash with eosinophilia and systemic symptoms (DRESS syndrome): an update. *Dermatology* 2003;206:353-6.
3. Arellano F, Sacristán JA. Allopurinol hypersensitivity syndrome: a review. *Ann Pharmacother* 1993;27:337-43.
4. Descamps V, Valance A, Edlinger C, Fillet AM, Grossin M, Lebrun-Vignes B, et al. Association of human herpesvirus 6 infection with drug reaction with eosinophilia and systemic symptoms. *Arch Dermatol* 2001;137(3):301-4.
5. Chopra S, Levell NJ, Cowley G, Gilkes JJ. Systemic corticosteroids in the phenytoin hypersensitivity syndrome. *Br J Dermatol* 1996;134(6):1109-12.
6. Michel F, Navellou JC, Ferraud D, Toussiot E, Wendling D. DRESS syndrome in a patient on sulfasalazine for rheumatoid arthritis. *Joint Bone Spine* 2005;72:82-85.
7. Schnetzke U, Bossert T, Scholl S, Freesmeyer M, Hochhaus A, La Rosée P. Drug-induced lymphadenopathy with eosinophilia and renal failure mimicking lymphoma disease: dramatic onset of DRESS syndrome associated with antibiotic treatment. *Ann Hematol* 2011;90(11):1353-5.
8. O'Meara P, Borici-Mazi R, Morton AR, Ellis AK. DRESS with delayed onset acute interstitial nephritis and profound refractory eosinophilia secondary to Vancomycin. *Allergy Asthma Clin Immunol* 2011;7:16.
9. Vauthey L, Uçkay I, Abrassart S, Bernard L, Assal M, Ferry T, et al. Vancomycin-induced DRESS syndrome in a female patient. *Pharmacology* 2008;82(2):138-41.
10. Tamagawa-Mineoka R, Katoh N, Nara T, Nishimura Y, Yamamoto S, Kishimoto S. DRESS syndrome caused by teicoplanin and vancomycin, associated with reactivation of human herpesvirus-6. *Int J Dermatol* 2007;46(6):654-5.
11. Kwon HS, Chang YS, Jeong YY, Lee SM, Song WJ, Kim HB, et al. A case of hypersensitivity syndrome to both vancomycin and teicoplanin. *J Korean Med Sci* 2006;21:1108-10.
12. Yazganoglu KD, Özkaya E, Ergin-Özcan P, Çakar N. Vancomycin-induced drug hypersensitivity syndrome. *J Eur Acad Dermatol Venereol* 2005;19:638-59.
13. Zuliani E, Zwahlen H, Gilliet F, Marone C. Vancomycin-induced hypersensitivity reaction with acute renal failure: resolution

following cyclosporine treatment. *Clin Nephrol* 2005;64(2):155-8.

**Raquel Díaz-Mancebo¹,
Olga Costero-Fernández¹,
Cristina Vega-Cabrera¹, Teresa Olea-Tejero¹,
Laura Yébenes², M. Luz Picazo²,
Rafael Selgas-Gutiérrez¹**

¹ Servicio de Nefrología. Hospital Universitario La Paz. Madrid. (Spain)

² Servicio de Anatomía Patológica. Hospital Universitario La Paz. Madrid. (Spain).

Correspondence: Raquel Díaz Mancebo
Servicio de Nefrología.
Hospital Universitario La Paz.
Paseo de la Castellana 261.
28046 Madrid. (Spain).
rdiazm.hulp@salud.madrid.org

Endovascular rescue of a prosthetic arteriovenous fistula with multiple pseudoaneurysms in a patient with no other vascular access options

Nefrologia 2012;32(5):687-9
doi:10.3265/Nefrologia.pre2012.Jul.11624

To the Editor:

The formation of pseudoaneurysms in prosthetic vascular accesses is a common event that is associated with fatigue of the prosthetic material secondary to repeated punctures and stenosis-occlusive damage in the venous drainage.¹

Treatment is indicated when the pseudoaneurysm undergoes rapid growth, exceeds 2 times the diameter of the prosthesis, produces pain or a threat to cutaneous viability, or in cases of rupture.¹

Traditionally, the treatment of this complication has been surgical; however, in recent years, several working groups have incorporated endovascular treatment using the placement of covered stents to exclude this type of lesion.^{2,3} Thrombin is not widely used as an embolising agent

during the treatment of these lesions, with only a few reports of cases in which this type of treatment has been associated with a stent graft.^{4,5}

CASE REPORT

Here we present the case of a 46-year-old patient with chronic renal failure, on trimetral haemodialysis for 23 years secondary to obstructive uropathy, with a left femoral loop (21 months of use) with occluded iliac venous drainage that produced oedema in the leg and three pseudoaneurysms in the therapeutic range. One of these was actively bleeding. The three pseudoaneurysms and occlusion of the left primitive iliac vein were treated using endovascular methods under local anaesthesia. The actively bleeding pseudoaneurysm was excluded with a covered stent, and the other two were percutaneously embolised using balloon-assisted thrombin injections in order to avoid thrombosis in the prosthesis. The iliac venous axis was recanalised and treated with angioplasty balloons; in the final angiographic controls, we observed no pseudoaneurysms, with patency of the prosthesis, iliac venous drainage, no signs of collateral circulation, and without having produced any complications.

DISCUSSION

Deterioration of the prosthetic material secondary to repeated punctures and stenosis-occlusive lesions in drainage veins represents one of the most common causes of pseudoaneurysms.¹ In our case, the prosthetic material was worn down, in addition to a stenosis/occlusive lesion of the venous drainage and bleeding of one of the pseudoaneurysms, with oedema in the leg.

Traditionally, pseudoaneurysms were treated with open surgery; this procedure consisted of replacing the damaged segment of the graft, and if this were impossible, the vascular access was abandoned and another was created. Our patient had exhausted all

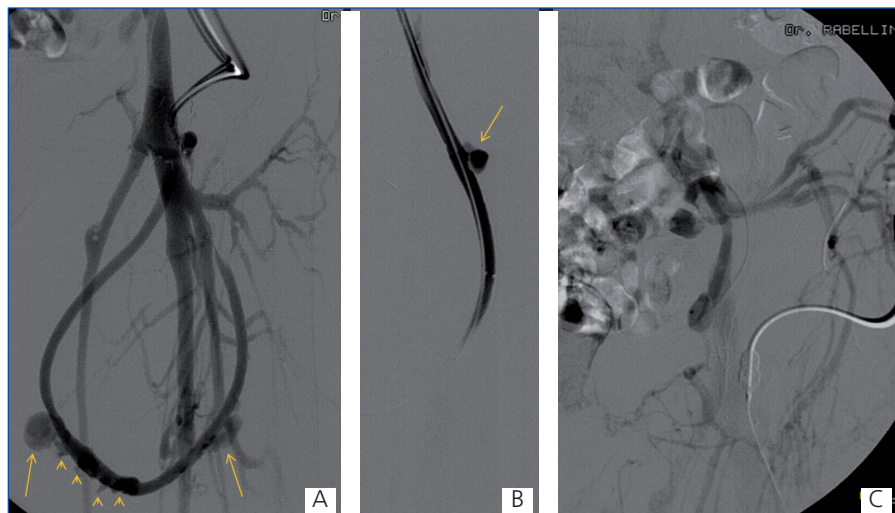

Figure 1. Fistulographies.

A and B: left femoral loop fistulography showing 3 pseudoaneurysms in the therapeutic range (arrows) and small pseudoaneurysms in the puncture site of the prosthesis (arrow heads), associated with venous hypertension in the limb. C: collateral circulation through the hypogastric venous branches due to stenosis of the external iliac vein and occlusion of the primitive iliac vein.

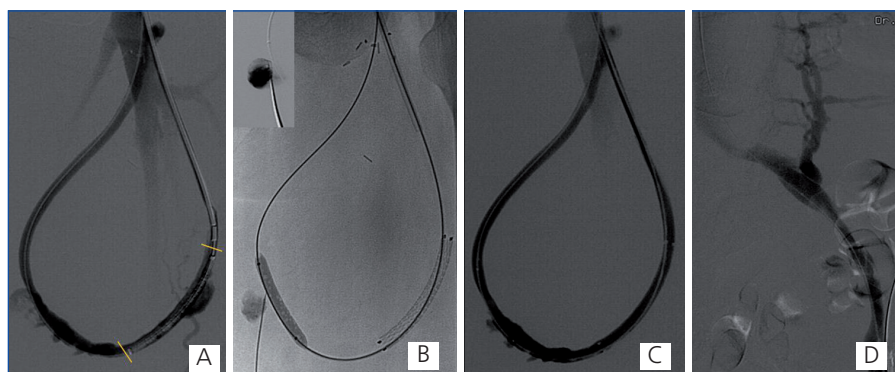


Figure 2. Stent, fluoroscopic images, and fistulography.

A: stent graft prior to release: lines delineate the proximal and distal ends of the stent. B: fluoroscopic images showing the balloon-assisted embolisation with thrombin technique in one of the non-bleeding pseudoaneurysms. Observe in the upper left quadrant the injection of contrast dye within each pseudoaneurysm prior to embolisation. C: control fistulography following treatment, revealing exclusion of the treated pseudoaneurysms with other small pseudoaneurysms that were below the therapeutic range, and an absence of reflux towards veins of the deep and superficial venous systems, as observed in Figure 1A. D: Patency of the left iliac venous axis following recanalisation and angioplasty, with a notable decrease in collateral circulation.

options of vascular access, for which we decided to preserve the existing one.

Since the first publication by Sapoval in 1996, several cases have been reported in which aneurysms and pseudoaneurysms of vascular accesses

were treated using an endovascular approach by placing a stent graft, with a success rate of as high as 100% according to some studies.^{2,3}

The use of thrombin as an embolising agent has been widely studied in the treatment of femoral pseudoaneurysms,

and this technique currently constitutes the standard practice for treating uncomplicated pseudoaneurysms. In the treatment of pseudoaneurysmal lesions of vascular accesses, we only have case reports of its isolated use⁴ or in association with a stent graft.⁵ Even so, we have not found any reference in the medical literature to the treatment of 3 pseudoaneurysms in the same patient using different techniques, in addition to revascularisation of the venous drainage system of a femoral loop.

Although the treatment of a vascular access with these characteristics may be the subject of debate, we believe that this was the best option in our case, since this was a patient with no other options for a vascular access.

Currently, endovascular treatment offers various alternatives for the treatment of this type of lesion, and so must be considered prior to programming surgery or abandoning the vascular access.

Conflict of interest

The authors declare that there is no conflict of interest associated with this manuscript.

1. Vascular Access 2006 Work Group. Clinical practice guidelines for vascular access. *Am J Kidney Dis* 2006; 48 Suppl 1:S176-247.
2. Vesely TM. Use of stent grafts to repair hemodialysis graft-related pseudoaneurysms. *J Vasc Interv Radiol* 2005;16(10):1301-7.
3. Barshes NR, Annambhotla S, Bechara C, Kougiaris P, Huynh TT, Dardik A, et al. Endovascular repair of hemodialysis graft-related pseudoaneurysm: an alternative treatment strategy in salvaging failing dialysis access. *Vasc Endovascular Surg* 2008;42:228-34.
4. Ananthakrishnan G, Bhat R, Severn A, Chakraverty S. Stent graft exclusion of pseudo-aneurysm arising from PTFE hemodialysis graft after recurrence following ultrasound guided thrombin injection. *J Vasc Access* 2008;9(4):293-5.
5. Keeling AN, Naughton PA, Mc Grath FP, Conlon PJ, Lee MJ. Successful

endovascular treatment of a hemodialysis graft pseudoaneurysm by covered stent and direct percutaneous thrombin injection. *Semin Dial* 2008;21(6):553-6.

Martín Rabellino¹, Guillermo Rosa-Diez², Esteban Mendaro¹, Soledad Crucelegui², Ricardo Posatini³, Ricardo García-Mónaco¹

¹ Servicio de Angiografía y Terapia Endovascular. Hospital Italiano de Buenos Aires. Ciudad Autónoma de Buenos Aires (Argentina).

² Servicio de Nefrología. Hospital Italiano de Buenos Aires. Ciudad Autónoma de Buenos Aires (Argentina).

³ Servicio de Cirugía Cardiovascular. Hospital Italiano de Buenos Aires. Ciudad Autónoma de Buenos Aires (Argentina).

Correspondence: Martín Rabellino
Servicio de Angiografía y Terapia Endovascular, Hospital Italiano de Buenos Aires, Pte. J. D. Perón, 4190, C1181ACH, Ciudad Autónoma de Buenos Aires, Argentina.
jmrabellino@hotmail.com

Senile adult with acute post-infectious glomerulonephritis

Nefrologia 2012;32(5):689-90

doi:10.3265/Nefrologia.pre2012.Jun.11581

To the Editor:

Acute post-infectious glomerulonephritis (APGN) is primarily a disease found in infants that occurs following infection of the respiratory tract or impetigo.^{1,2}

This disease is uncommon in older patients, but aging has become an important risk factor. Four decades ago, only 4%-6% of adults with APGN were older than 65 years of age, compared to 34% in recent reports.³

Comorbidities such as decreased renal function, diabetes mellitus, arterial hypertension, hyperlipidaemia, cardiovascular disease, and neoplasia contribute to the modification of the clinical pres-

entation and natural progression of this condition. APGN is present in 3%-6% of biopsies, and is often an unexpected finding. Renal function is recovered within 3-4 weeks in 95% of cases, although this rate is much less predictable in the elderly.^{1,3,4}

The treatment of APGN is based on antibiotics, diuretics, hypotensive drugs, and occasionally haemodialysis.^{2,5}

We present four cases of patients older than 55 years with acute renal failure and nephritic syndrome, three of which were preceded by a respiratory infection and substantially elevated creatinine levels, and the fourth of which had nephritic/nephrotic syndrome with no prior infection and conserved renal function.

Case A: A 59-year-old male with chronic kidney disease (CKD) and rheumatoid arthritis, hospitalised due to nephritic syndrome in the context of a cutaneous infection by methicillin-re-

Table 1. Clinical and laboratory values

Age	59 years	64 years	80 years	83 years
Arterial hypertension	Yes	Yes	Yes	Yes
Oedema	Yes	Yes	No	Yes
Haematuria	250/μl	250/ul	Macroscopic	250/μl
Leukocyturia	Negative	Negative	100/μl	100/μl
Proteinuria	150mg/dl	2.6g/24 h	500mg/dl	13g/24 h
Creatinine	4.3mg/dl	1mg/dl	5.8mg/dl	6.1mg/dl
C3	Normal	Normal	Normal	Normal
ASLO	Normal	Normal	Normal	Normal
FR/ANCA/ANA/anti-MBG	Negative	p-ANCA (+) 1/320	Negative	Negative
Infection	Respiratory and cutaneous	None	Respiratory	Orchitis/epididymitis and respiratory
Treatment	Prednisone 1mg/kg	None	ATB + HD	ATB + prednisone 1mg/kg + HD
Evolution of creatinine	2.4mg/dl	1mg/dl	7.8mg/dl HD	HD
Evolution of proteinuria	300mg/24 h	1.2g/24 h	HD	HD

ANA: anti-nuclear antibodies; ANCA: anti-neutrophil cytoplasmic antibodies; HD: haemodialysis